

Pleomorphic Adenoma of the Palate: A Case Report

AMIT KUMAR GOTHWAL, ANAGHA KAMATH, RAJDEEP S. PAVASKAR, SUJATA K. SATOSKAR

ABSTRACT

Pleomorphic adenoma, also called benign mixed tumour, is the most common tumour of the salivary glands. About 90% of these tumours occur in the parotid gland and 10% of them occur in the minor salivary glands. The most common sites for pleomorphic adenoma of the minor salivary glands are the palate, followed by the lips and the cheeks. Other rare sites include the floor

of the mouth, tongue, tonsil, pharynx, the retromolar area and the nasal cavity. Here, we are reporting a case of pleomorphic adenoma of the minor salivary glands of the palate in a 36-year old Indian male. The mass was removed by wide local excision with adequate margins under GA. There were no recurrences after a follow-up period of 8 months.

INTRODUCTION

Pleomorphic adenomas are benign salivary gland tumours that represent about 3-10% of the neoplasms of the head and neck region [1]. They are the most common tumours (50%) of the major and the minor salivary glands [2]. The palate is considered as the most common intra-oral site (42.8-68.8%), followed by the upper lip (10.1%) and the cheeks (5.5%) [3, 5]. Other rare sites include the throat (2.5%), the retromolar region (0.7%), the floor of the mouth and the alveolar mucosa [4]. Pleomorphic adenoma usually presents as a mobile, slowly growing, painless, firm swelling that does not cause ulceration of the overlying mucosa [6]. Pleomorphic adenoma consists of cells with epithelial and mesenchymal differentiation (mixed tumour). The highly variable morphology of this neoplasm is the result of the interplay between these elements. Now, it has been widely accepted that both epithelial and mesenchymal (myxoid, hyaline, chondroid and osseous) elements often arise from the same cell clone, which may be a myoepithelial or a ductal reserve cell. Lee et al examined formalin-fixed, paraffin-embedded tissues from 13 pleomorphic adenomas of female patients and the findings from them suggested that the stromal and epithelial cells in pleomorphic adenomas of the salivary gland arose from the same clone in most of the cases [7]. The variants of pleomorphic adenoma include pleomorphic adenoma with a lipomatous change, myxoliomatous pleomorphic adenoma, pleomorphic adenoma with a squamous differentiation and benign metastasizing mixed tumour [8].

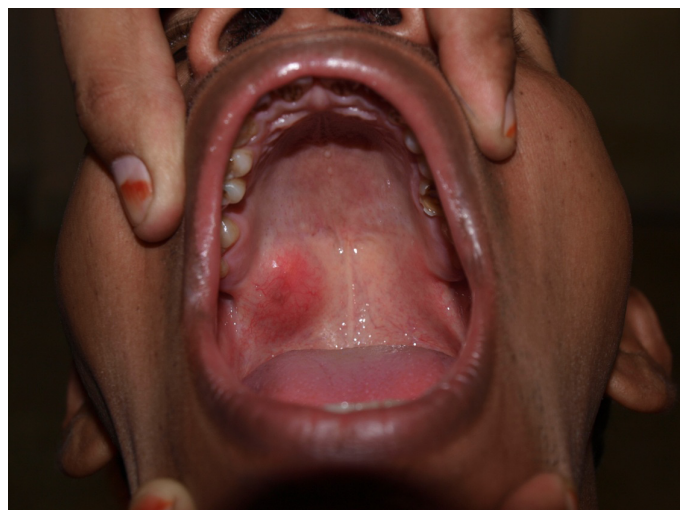CASE REPORT

A 39-year-old male reported to the Department of Oral Medicine and Radiology with the chief complaint of a non-painful swelling over the right palatal region since the last one and a half months. The swelling was not interfering with mastication; there was no history of trauma or fever. The past medical history, the past dental history, the family history and the social history were not relevant. The patient gave a history of occasional tobacco chewing and cigarette smoking. On general examination, it was found that the patient was of normal build and height. His vital signs were normal

Key Words: Pleomorphic adenoma, Minor salivary gland, MRI

and no abnormality was detected on his systemic examination. Extraorally, there was no facial asymmetry, and no evidence of any trauma. Nothing abnormal was detected on examination of the lymph nodes. His intra-oral examination revealed a single domed shaped swelling which approximately measured 2 × 3 cms, which extended ≈7 mm from the marginal gingiva in relation to the right first molar to the right third molar region, not crossing the midline [Table/Fig-1]. The overlying mucosa was not ulcerated and it was mobile over the swelling. On palpation, the swelling was found to be soft in consistency, compressible and non tender. On the basis of the history and the clinical examination, a provisional diagnosis of benign tumour of the minor salivary gland was made and a differential diagnosis of malignant tumour of the minor salivary gland and lipoma was considered.

The radiograph of the maxilla (occlusal view) did not show any bony invasion. A computed tomography (CT) scan of the palate was performed by taking 3 mm spiral axial sections and the CT

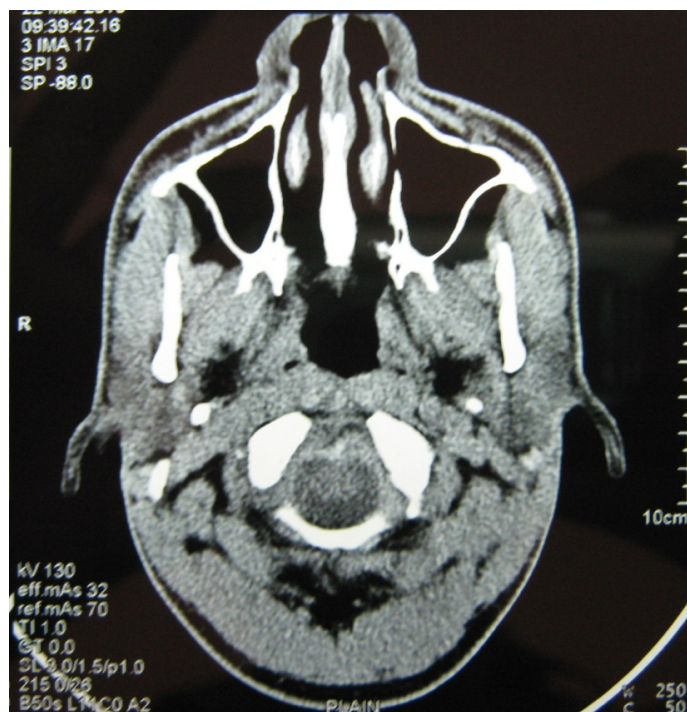

[Table/Fig-1]: A single domed shaped swelling measuring approximately 2 × 3 cms, extending ≈7 mm from marginal gingiva in relation to right first molar to right third molar region, not crossing the midline.

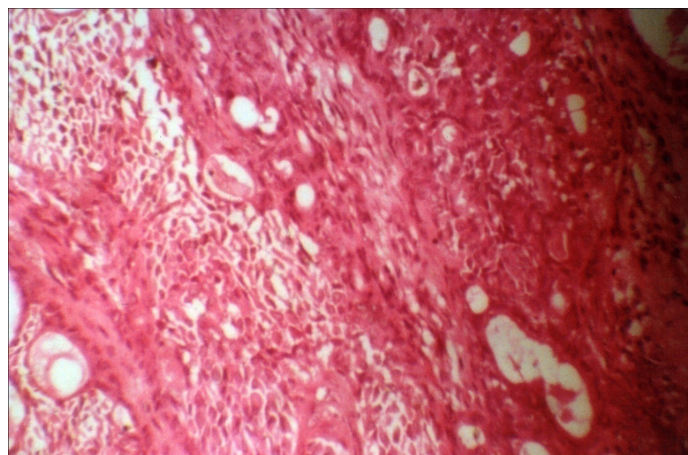
scan report revealed a homogenously enhancing, well-defined hypodense lesion which measured 2.0 × 2.3 cms in the right posterolateral wall of the soft palate, with no bony invasion [Table/Fig-2]. A wide local excision with adequate margins was done under GA and the histopathological report of the biopsy specimen confirmed the diagnosis of pleomorphic adenoma [Table/Fig-3].

DISCUSSION

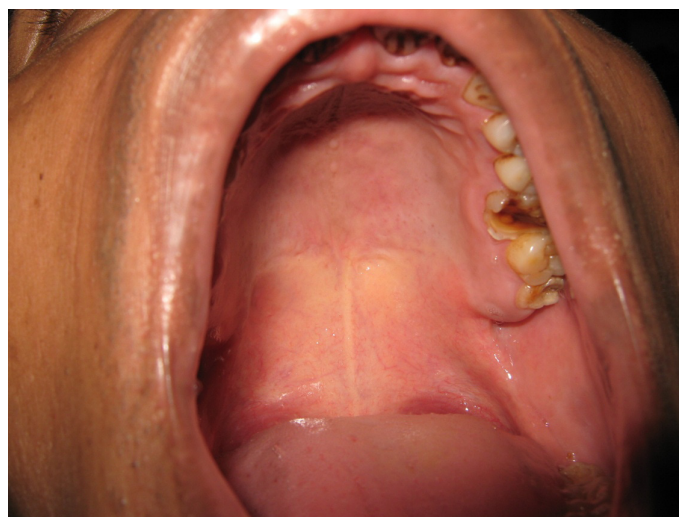
Muco-epidermoid carcinoma is the most common malignant salivary gland tumour, while pleomorphic adenoma is its most common benign counterpart. The differential diagnosis for this case includes malignant tumour of the minor salivary gland and lipoma. Plain X-rays and haematologic investigations play no part in the diagnosis of salivary gland tumours of the palate. CT is superior to MRI in evaluating the erosion and the perforation of the bony palate, or the involvement of the nasal cavity or the maxillary sinus. MRI provides a better definition of the vertical and inferior tumour extension and it more accurately indicates the degree of encapsulation [9,10] MRI is also advantageous because of the absence of the exposure to radiation and because of the intravenous contrast



[Table/Fig-2]: Homogenously enhancing well-defined hypodense lesion measuring 2.0 × 2.3 cms in the right posterolateral wall of soft palate with no bony invasion.



[Table/Fig-3]: Histopathological report of the biopsy specimen



[Table/Fig-4]: After 8 month of follow-up

medium. A histological diagnosis is essential to plan the definitive management. The treatment consists of wide local excision with clear margins which involves the periosteum and the associated mucosa, followed by curettage of the underlying bone with a curette or bur under copious, sterile, normal saline irrigation [10]. The overlying mucosa can sometimes be repaired by using a local flap. In our case, the patient did not require reconstruction as the palatal mucosa was regenerated and as there was no oro-antral fistula formation. Pleomorphic adenoma is encapsulated, and an incomplete excision can leave behind residual tumour cells, resulting in recurrence, because of its high rate of implantability. Our patient has not experienced any recurrence after 8 months of follow-up [Table/Fig-4].

CONCLUSION

This case represents a classic example of pleomorphic adenoma of the palate. Successful treatment begins with an appropriate referral and a biopsy-proven diagnosis. Computed tomography aids in evaluating the extent of the lesion and in guiding the surgical strategy. A long-term follow-up is warranted because of the risk of recurrence even several years after the initial excision.

ACKNOWLEDGEMENTS

The authors are grateful to Dr. Anita Meena, post-graduate student in the Department of Conservative Dentistry and Endodontics, Government Dental College and Hospital, Jaipur, Rajasthan, for her contribution in providing related articles and her constant support. We also thank the patient for giving the consent to report this case.

REFERENCES

- [1] Garcia Berrocal JR, Ramirez Camacho R, Trinidad A, Salas C. Mixed tumour (pleomorphic adenoma) of the head and neck. Typical and atypical patterns. *An Otorrinolaringol Ibero Am* 2000;27:333-40.
- [2] Traiger J, Rosen MB. Mixed tumor of the cheek; report of a case. *Oral Surg Oral Med Oral Pathol* 1965; 19:711-14.
- [3] Van Heerden WF, Raubenheimer EJ. Intra-oral salivary gland neoplasms: a retrospective study of seventy cases in an African population. *Oral Surg Oral Med Oral Pathol* 1991;71:579-82.
- [4] Wang D, Li Y, He H, Liu L, Wu L, He Z. Intra-oral minor salivary gland tumors in a Chinese population: a retrospective study on 737 cases. *Oral Surg Oral Med Oral Pathol Oral Radiol Endod* 2007; 104:94-100.
- [5] Toida M, Shimokawa K, Makita H, Kato K, Kobayashi A, Kusunoki Y, et al. Intra-oral minor salivary gland tumors: a clinicopathological study of 82 cases. *Int J Oral Maxillofac Surg* 2005;34:528-32.

- [6] Kaminski M, Janicki K. A case of giant pleomorphic adenoma of the cheek with two malignant centers. *Otolaryngol Pol* 2002;56:385-87.
- [7] Lee PS, Sabbath-Solitare M, Redondo TC, Ongcapin EH. Molecular evidence that the stromal and epithelial cells in pleomorphic adenomas of the salivary gland arise from the same origin: clonal analysis by using the human androgen receptor gene (HUMARA) assay. *Hum Pathol* 2000; 31:498-503.
- [8] Kondo T. A case of lipomatous pleomorphic adenoma in the parotid gland. *Diagn Pathol* 2009; 4:16.
- [9] Rodríguez-Fernández J, Mateos-Micas M, Martínez-Tello FJ, Berjón J, Montalvo JJ, Forteza-González G, et al. Metastatic benign pleomorphic adenoma. Report of a case and review of the literature. *Med Oral Patol Oral Cir Bucal*. 2008; 13:193-96.
- [10] Mubeen K., Vijayalakshmi K.R., Pati A.R et al. Benign pleomorphic adenoma of the minor salivary gland of the palate. *Journal of Dentistry and Oral Hygiene*. 2011; 3:6:82-88.

AUTHOR(S):

1. Dr. Amit Kumar Gothwal
2. Dr. Anagha Kamath
3. Dr. Rajdeep S. Pavaskar
4. Dr. Sujata K. Satoskar

PARTICULARS OF CONTRIBUTORS:

1. MDS Student
Department of Oral Medicine and Radiology
Govt. Dental College & Hospital
Bambolim-Goa, India, 403 202
2. MBBS, M.D, Assistant Professor
Kasturbha Medical College, Mangalore, India
3. MDS student
Conservative Dentistry and Endodontics Dept.
Goa Dental College and Hospital
Bambolim, Goa, India

4. Sujata K. Satoskar MDS, Assistant Professor
Department of Oral Medicine and Radiology
Govt. Dental College & Hospital
Bambolim-Goa, India 403 202.

NAME, ADDRESS, E-MAIL ID OF THE CORRESPONDING AUTHOR:

Dr. Amit Kumar Gothwal
Department of Oral Medicine and Radiology
Goa Dental College & Hospital (GDC&H)
Bambolim-Goa, India 403 202
Phone: +91- 9373819472
E-mail: drgothwal07@gmail.com; anumitagothwal@gmail.com

FINANCIAL OR OTHER COMPETING INTERESTS:

None.

Date of Submission: **Sep 15, 2011**
Date of peer review: **Nov 03, 2011**
Date of acceptance: **Dec 22, 2011**
Date of Publishing: **Aug 10, 2012**